

**PATIENT**

Taz Bartholomew

**PRESENTING CLINICAL SIGNS**

re check from 5/7 Eating well , hasnt vomited

**LIMITED ULTRASONOGRAPHIC EXAMINATION OF THE ABDOMEN**

**SPECIES**

Feline

**Gastrointestinal**

The stomach was empty. The small intestine revealed persistent hypertrophied muscularis. No progression from the prior sonogram.

**BREED**

DSH

**Pancreas**

The pancreas in this patient revealed mild residual heterogenous parenchymal changes without evidence of abscessation.

**SEX**

MN

**Free Abdomen**

Minor reactive lymph nodes noted up to 5 mm.

**AGE**

16

**ULTRASONOGRAPHIC FINDINGS**

- Resolved pancreatic presentation
- Persistent minor intestinal thickening, likely underlying inflammatory bowel

**WEIGHT**

13.8

**INTERPRETATION OF THE FINDINGS & FURTHER RECOMMENDATIONS**

Continued medical management indicated. Recheck sonogram as deemed necessary, yet the pancreas appears to be stabilizing.

**INTERPRETED BY**

Eric Lindquist, DMV  
DABVP, Cert. IVUSS

**IMAGING PERFORMED BY**

Jenn

**HOSPITAL NAME**

Rockaway Animal Hospital

**REFERRING VET**

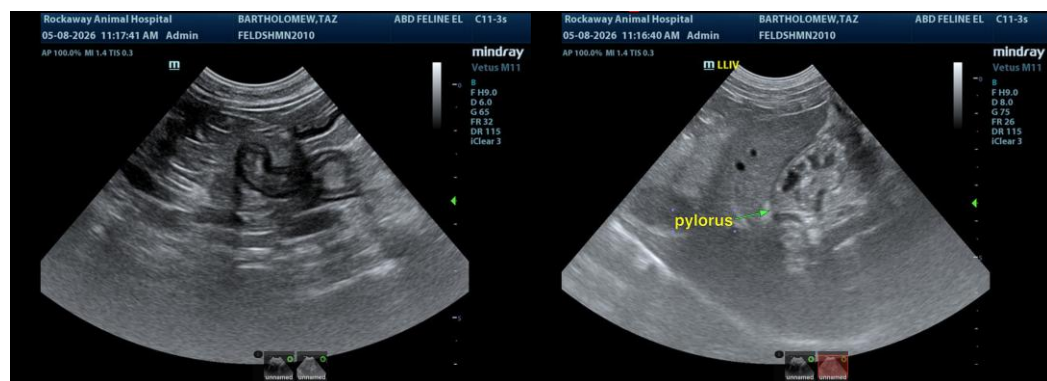
Dr Maniar

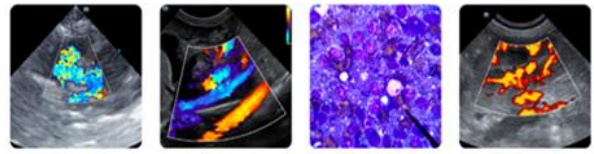
**INVOICE**

24749

**DATE**

05/08/2026





## PATIENT

Taz Bartholomew

## SPECIES

Feline

## BREED

DSH

## SEX

MN

## AGE

16

## WEIGHT

13.8

## INTERPRETED BY

Eric Lindquist, DMV  
DABVP, Cert. IVUSS

## IMAGING PERFORMED BY

Jenn

## HOSPITAL NAME

Rockaway Animal  
Hospital

## REFERRING VET

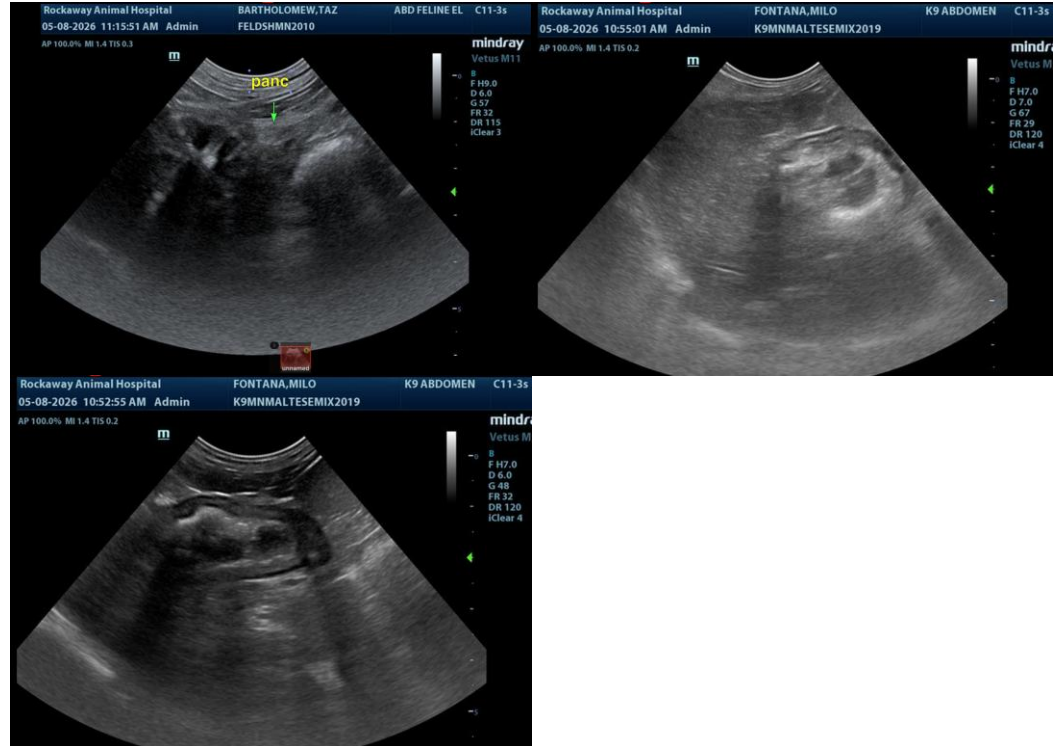
Dr Maniar

## INVOICE

24749

## DATE

05/08/2026



The information and recommendations provided are based on the images presented by the referring veterinarian/sonographer. No evaluation can be communicated regarding pathology that was not visible in the image/video clips provided.

Thank you for this referral. If the clinical or image interpretation does not parallel your findings or if I can be of any further assistance, please contact me.

Eric Lindquist, DMV, DABVP(CFM), Cert. IVUSS,  
CEO, Owner, Founder -- SonoPath.com  
info@SonoPath.com